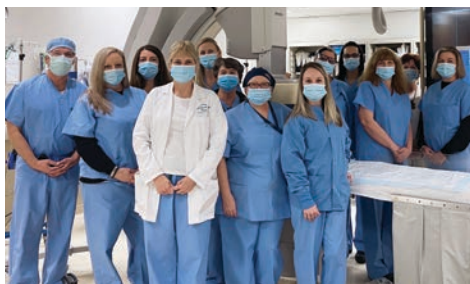

Cath Lab Digest

A product, news & clinical update for the cardiac catheterization laboratory specialist



CATH LAB SPOTLIGHT

Lowell General Hospital's Heart and Vascular Center

Allayne Mendys, MBA, BSN/RN, CV-BC, AACCC, Clinical Manager; Stacey Cayer, BSN/RN; Deidre Goad, RT(R); Anne Marie Jussaume, RT(R); and Laura Pruyun, BSN/RN, CV-BC; Lowell, Massachusetts

Tell us about your cath lab and facility.

Our cath lab is part of a 390-bed community hospital located in Lowell, Massachusetts. Our mission aligns with that of the hospital: we put "Patients First in Everything We Do". The staff and cardiologists are patient-oriented, and strive to provide the highest quality care and services. The Heart and Vascular Center is part of a service line that meets quarterly. We look at how we can grow in our region, improve services for our patients, and collaborate with our partnering hospitals under the Wellforce system, which includes Tufts Medical Center and MelroseWakefield Hospital.

continued on page 28

In This Issue

The Langston is Gone For Now (No More Dual Lumen Pigtail for Aortic Valve Assessment). Now What?

Morton J. Kern, MD, et al
page 6

Patient With COVID-19 Infection and Abnormal Stress Test

Syed M. Ahmed, MD
page 22

Twisted Turns to Traverse — Our Approach to Upper Extremity Tortuosity

Gautam Kumar, MBBS, MRCP(UK), FASE, FACC, FSCAI, and Rajesh Sachdeva, MD, FACC, FSCAI
page 24

RCA Perforation Sealed With PK Papyrus Stent

Monarch Shah, MD; Henil Patel, MD; Radhika-Alicia Patel; Shay Awasti; Ashish Awasti, MD; Pratik Patel, MD
page 40

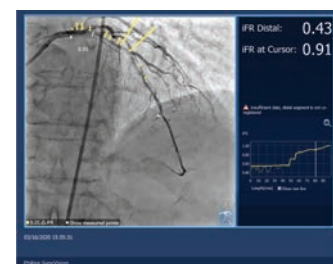CLINICAL TRIAL UPDATE

Evaluating Post-PCI iFR and Optimal Revascularization in DEFINE PCI

Use of physiology with Philips iFR, OmniWire, and iFR Co-registration with upcoming DEFINE GPS

Talking with Allen Jeremias, MD, MSc,* and Ziad A. Ali, MD, DPhil.
*Dr. Jeremias is the Principal Investigator for DEFINE PCI and DEFINE GPS.

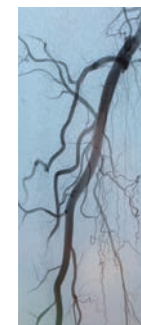
The DEFINE PCI (Physiologic Assessment of Coronary Stenosis Following PCI) study¹ suggests that percutaneous coronary intervention (PCI) guided by instantaneous wave-free ratio (iFR) can improve outcomes and reduce angina for patients more effectively than treatment guided by angiography alone. The trial assessed the level of residual ischemia found in patients following PCI using a blinded iFR pullback measurement. At one year, patients with a post-PCI iFR measurement ≥ 0.95 had improved outcomes and less recurrent angina. A post-PCI iFR of ≥ 0.95 was also associated with improved event-free survival at 1 year and 68% fewer clinical events at 1 year compared with patients with less than optimal post-PCI iFR values (1.8% vs 5.7%, $P=.04$). DEFINE PCI also revealed that 24% of patients with angiographically successful PCI had residual ischemia, and in approximately 82% of these patients, it was the result of a focal, potentially treatable lesion.



continued on page 12

CASE REPORT & INTERVIEW

Using Directional Atherectomy for the Revascularization of Chronic Total Occlusions in Critical Limb Ischemia



James F. Foster III, MD, RVPI, and Miles McKee, DO

continued on page 16

Continued from cover

Using Directional Atherectomy for the Revascularization of Chronic Total Occlusions in Critical Limb Ischemia

James F. Foster III, MD, RVPI, and Miles McKee, DO

As endovascular treatment options have improved over the years, it is now possible to treat lesions with a minimally invasive approach that would have previously required a surgical intervention.¹ For example, the REALITY clinical study demonstrated that endovascular treatments, specifically, the HawkOne™ Directional Atherectomy System (Medtronic) followed by an IN.PACT™ Admiral™ Drug-Coated Balloon (Medtronic), resulted in good clinical outcomes in even some of the most challenging conditions, including long lesions and chronic total occlusions (CTOs), with a 92.6% freedom from clinically driven target vessel revascularization (FF-CD TLR) rate.²

Furthermore, since peripheral arterial disease is progressive, it is important to leave future treatment options open by using techniques to minimize the rate of stenting. One way is through the use of HawkOne™ Directional Atherectomy System prior to adjacent therapies. In the IN.PACT Global Study, which looked at the results of angioplasty alone, the provisional stent rate was 21.2% with a 35.5% rate of CTOs and a mean lesion

length of 12.09±9.54 cm.³ In contrast, REALITY, which had a CTO rate of 39% and average lesion length of 17.9 cm, had a low 8.8% stent rate.² Another directional atherectomy study, DEFINITIVE LE, which had an occlusion rate of 20.8% and average lesion length of 7.4±5.3 cm, had an even lower 3.2% stent rate.⁴ While these studies cannot be directly compared head-to-head, the results suggest a trend toward lower stent rates with the use of directional atherectomy prior to adjunctive treatment.

Case 1

A male in his early 70s presented to clinic for evaluation of his bilateral lower extremity pain with ambulation and a right-sided nonhealing foot ulcer. Upon ambulating short distances (~20 ft), his leg would become weak and painful, limiting his daily independence and autonomy. After evaluation, he was noted to have bilateral superficial femoral artery (SFA) chronic total occlusions and he was taken for a right lower-extremity angiogram with possible intervention.

Ultrasound-guided 6 French (Fr) access was gained in the left common femoral artery (CFA) for a full diagnostic angiogram of the right leg. The patient was found to have a patent right CFA and profunda with a flush occlusion of the right SFA reconstituting at the abductor hiatus. The popliteal artery was also patent and the patient had 3-vessel runoff extending down to the ankle, with the posterior tibial and dorsalis pedis arteries extending into the pedal arch (Figure 1).

Prior to treatment, the 6 Fr sheath was exchanged for a 7 Fr 45 cm Destination® sheath (Terumo) that was parked in the right CFA. Using a 4 mm x 200 mm balloon, the lesion was predilated over an .014-inch wire in the anterior tibial. Directional atherectomy of the SFA lesion was then performed using the HawkOne™ Directional Atherectomy System. For this procedure, one pass was taken in each quadrant.

Post-atherectomy intravascular ultrasound (IVUS) assessment of the right lower extremity was performed to assess the vasculature from the CFA down to the anterior tibial artery and tibioperoneal trunk. The use of IVUS confirmed the angiographic diagnosis of atherosclerotic disease and intimal hyperplasia associated with the right SFA. IVUS was also used to size the SFA and popliteal for post-dilation using drug-coated balloon angioplasty. A 6 mm IN.PACT™ Admiral™ Drug-Coated Balloon was used for this case.

Post-procedure angiography (Figure 2) showed a widely patent SFA with no residual stenosis extending into the above-knee popliteal artery with a maintained trifurcation and 3-vessel runoff to the right foot. The patient was discharged and his right foot ulcer proceeded to heal. He no longer has right leg pain.

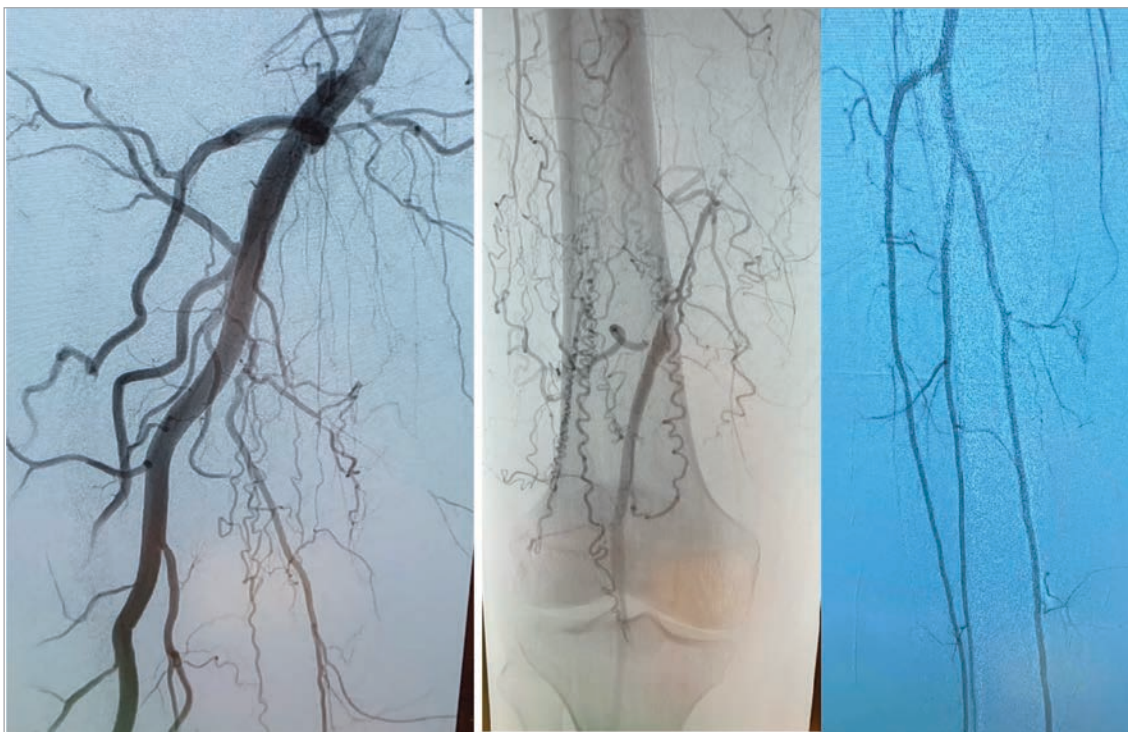


Figure 1. Case 1. Diagnostic angiography showing an occlusion of the SFA with a patent popliteal and 3-vessel runoff.

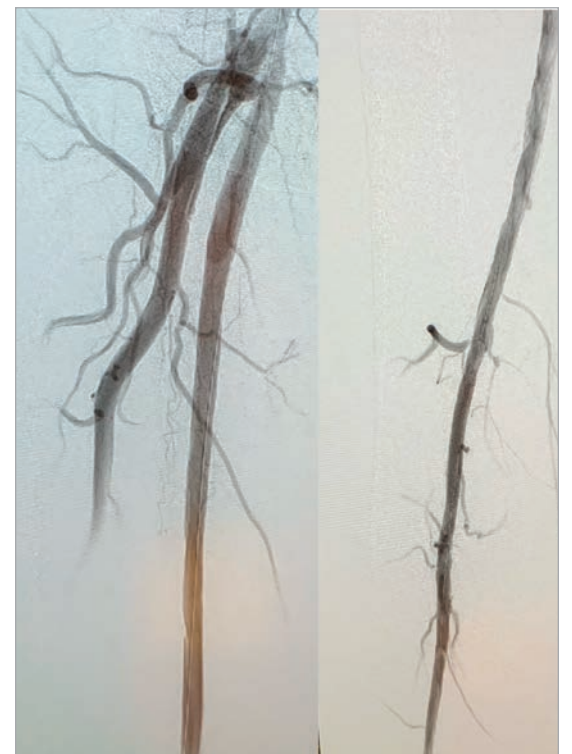


Figure 2. Case 1. Post-procedure angiography.

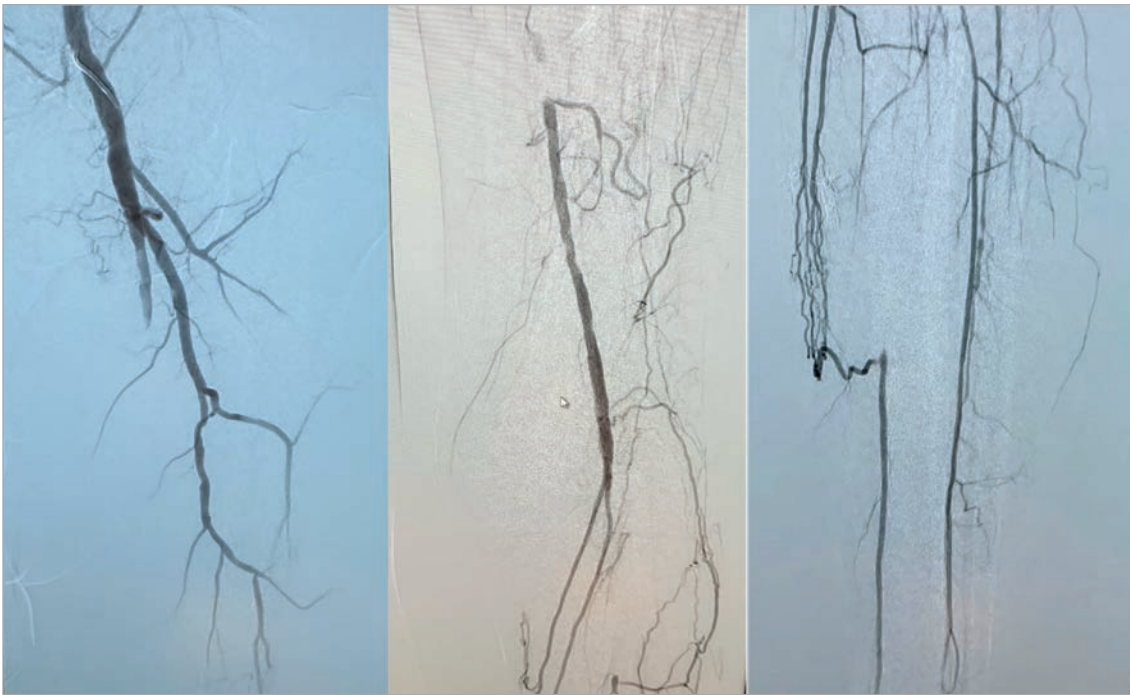


Figure 3. Case 2. Pre-procedure angiography of left leg, showing multilevel disease.

Directional atherectomy is a good tool to have when treating CLI. Medtronic's HawkOne™ M device is versatile enough to treat the above- and below-knee multilevel disease often encountered in this patient group, offering procedural efficiency.

Case 2

In this case, the patient was a non-smoking male in his early 70s, presenting with critical limb ischemia of the left lower extremity. After evaluation in the clinic, he was offered a left lower-extremity angiogram with possible intervention. This patient presented with significant comorbidities, including atherosclerosis, type 2 diabetes mellitus, hypertension, chronic protein-calorie malnutrition, and hemiplegia with hemiparesis following cerebral infarction.

Ultrasound guidance was used to access the right CFA for angiography. Angiography revealed multilevel disease of the left SFA and popliteal, as well as the posterior tibial (Figure 3). After crossing the entirety of the disease with a Trail-Blazer™ Support Catheter (Medtronic), luminal positioning was confirmed on angiography. The lesions were then pre-dilated with a long 3 mm Chocolate™ PTA Balloon Catheter (Medtronic).

Directional atherectomy was then performed in the distal left CFA, SFA, and popliteal using 4 passes of the HawkOne™ M device. Using the same device, atherectomy of the posterior tibial artery was also performed; however, only 2 passes were made, one medial and one lateral. Angiography was performed directly after atherectomy, showing in-line flow to

the superficial femoral artery and posterior tibial artery down into the foot (Figure 4).

As is our preferred practice, we then performed an IVUS assessment of the left common iliac down to the posterior tibial arteries, confirming patency and allowing for a more accurate vessel sizing for adjunctive balloon angioplasty. The SFA was treated with a 6 mm IN.PACT™ Admiral™ Drug-Coated Balloon, using a 3-minute inflation time. The popliteal was similarly treated with a 5 mm IN.PACT™ Admiral™ Drug-Coated Balloon. Adjunctive angioplasty of the posterior tibial artery was performed with a 3 mm Chocolate™ PTA Balloon.

Post angioplasty, a completion angiogram was performed (Figure 5), showing complete resolution of the disease, with in-line flow now extending through the CFA and SFA into the popliteal artery and down into the foot via the posterior tibial artery. The patient was subsequently discharged home on dual antiplatelet therapy. After repeat debridement, the patient's ulcers healed and he is no longer having associated pain. He has maintained a palpable posterior tibial on repeat exam and will continue to be monitored with serial duplex studies to follow his arterial pathology.

Interview With the Operator

James F. Foster III, MD, RVPI



Can you tell us about your center and practice?

Centerpoint Medical Center is a 285-bed hospital that has state-of-the-art vascular equipment, including a hybrid room. It is also the second busiest emergency department in the Kansas City metro area, with about 50,000+ visits a year. Centerpoint is a level II trauma center, although it essentially functions as a level I trauma center. We have a big catchment area in Eastern Jackson County, gather a fair amount of patients from Jackson County in the metro area, and we also have a good amount of rural referrals. Once or twice a month, I travel northeast to Carrollton County for an outreach clinic serving rural-based patients who need vascular care for peripheral vascular disease or critical limb ischemia (CLI). We take care of the majority of these cases at Centerpoint Medical Center. It is an extremely busy, high-volume practice.

Can you describe your procedure balance?

I do a mix of open and endovascular procedures, but the balance leans more toward endovascular, perhaps 80%. While I have never been one to push the envelope in endovascular treatment, the technology for these types of interventions keeps getting better and better, such that we can now achieve good revascularization success and clinical outcomes with minimally invasive approaches.

Do you have a typical pathway for endovascular revascularization?

My endovascular procedural goal is to minimize any metal left behind in the patient. If there is a fem-pop lesion, I use directional atherectomy with the HawkOne™ system (Medtronic), which allows me to specifically target the lesion. I truly believe in the value of prepping the vessel with directional atherectomy and I have seen better clinical outcomes since I began using directional atherectomy followed by drug-coated balloon angioplasty, especially long-term primary patency results in the femoral-popliteal arterial system. I place a stent less than 5% of the time and this percentage went down once I started using more IVUS due to a lower dissection rate. Previously, I was sizing these vessels based on angiography versus what I can see with IVUS inside the vessel, such as the amount of intimal hyperplasia. Vessel wall outer to outer diameter can sometimes significantly differ based on your lumen wall. If you over dilate, you are prone to having dissections.

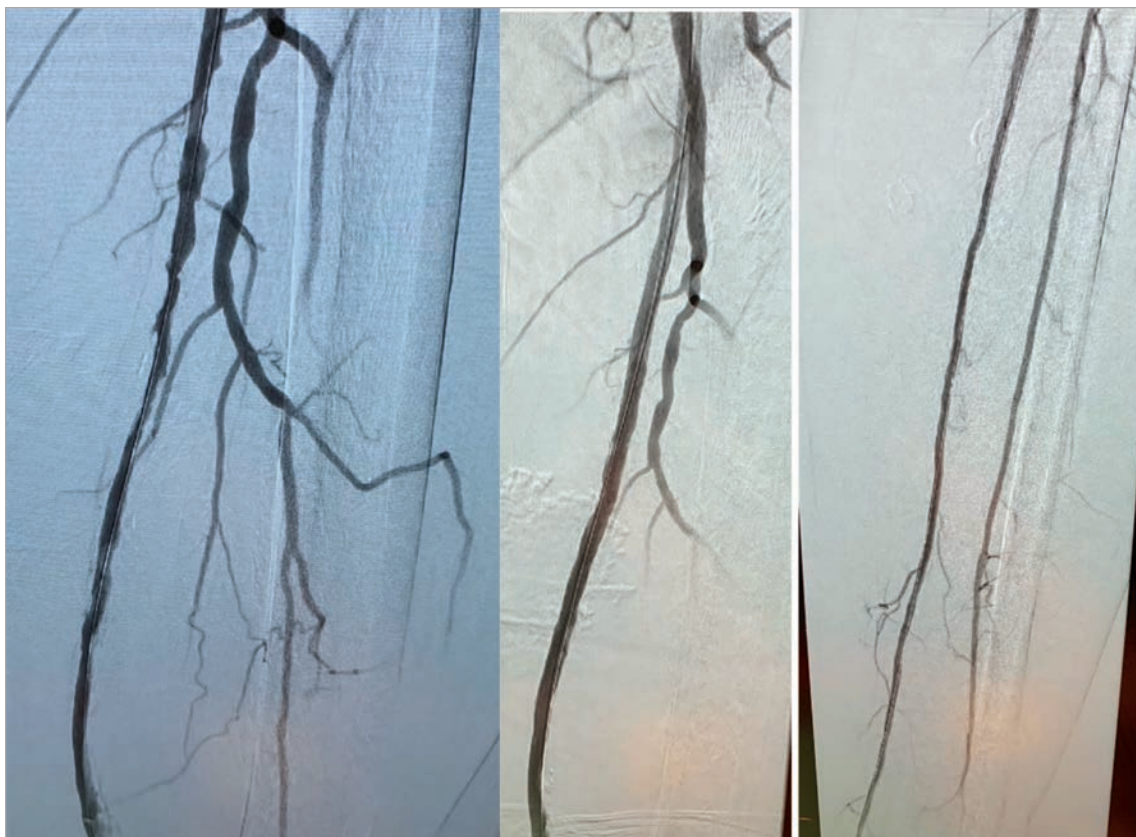


Figure 4. Case 2. Angiography post HawkOne™ Directional Atherectomy, with 4 passes from the CFA to the popliteal and 2 passes in the posterior tibial.

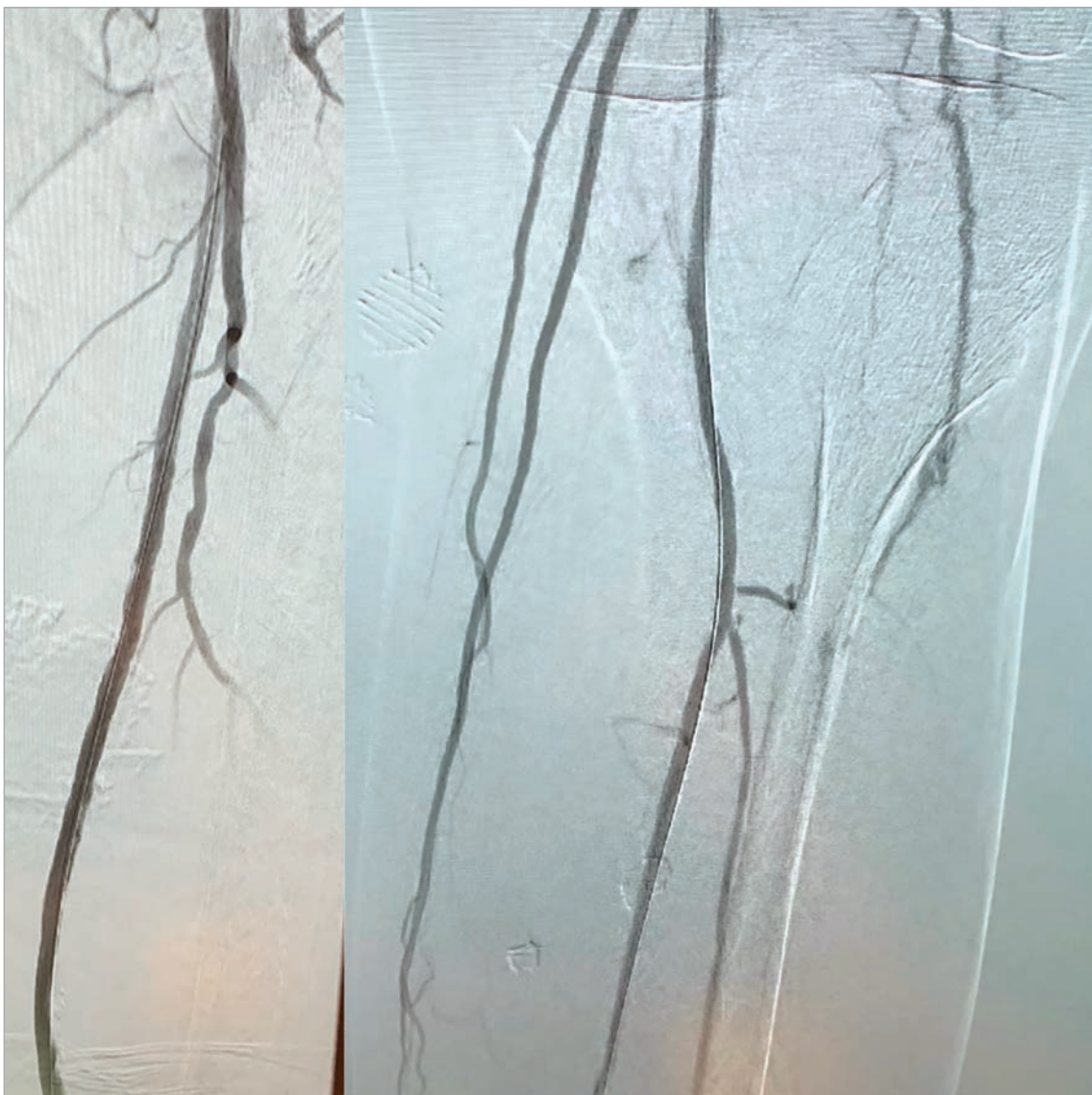


Figure 5. Case 2. Post-procedure angiography of the limb.

Has the awareness of critical limb ischemia increased among your referring physicians?

Pre COVID, CLI awareness was definitely rising. COVID put a unique constraint on our communication with referring physicians. Historically, we would make a couple of trips each month to primary care physicians, and give grand rounds or brief presentations over lunch regarding the evolving field of vascular surgery and what we can do for patients. That has essentially stopped as of now. We have transitioned to Zoom meetings, and we need to continue to be creative and think about moving forward. There is still plenty of educational ground to gain regarding vascular patients specifically, and small subsets of those patients, particularly critical limb ischemia.

I truly believe in the value of prepping the vessel with directional atherectomy. I have seen better clinical outcomes since I began using directional atherectomy followed by drug-coated balloon angioplasty.

What are the current challenges and some of the positives of CLI treatment today?

I will start with some of the good things. I came out of fellowship in 2016 and since that time, have transitioned from the use of rotational atherectomy to directional atherectomy. Rotational atherectomy is pretty easy. You pick a crown, you throw it up and down the artery, and you are done. Directional atherectomy requires more precision. However, in my experience, it is not more technically demanding than rotational atherectomy. Once I transitioned over, I found that directional atherectomy is fast, efficient, intuitive, and easy to use. My clinical outcomes have improved, because I can now target lesions. Regardless of whether the disease was concentric or eccentric, I can focus my atherectomy on where the plaque is located. I am no longer at the mercy of whatever atherectomy device

Conclusions

Directional atherectomy is a good tool to have when treating CLI. Medtronic's HawkOne™ M device is versatile enough to treat the above- and below-knee multilevel disease often encountered in this patient group, offering procedural efficiency. It also allows the operator the freedom to choose how aggressively to treat the lesion prior to adjunctive therapy. It provides options ranging from a single pass or two to change vessel compliance to many passes in order to remove disease and maximize luminal gain. The risk of dissection and need for bailout stenting are also reduced when using directional atherectomy, leaving more options available for future interventions. ■

References

1. Thukkani AK, Kinlay S. Endovascular intervention for peripheral artery disease. *Circ Res*. 2015 Apr 24; 116(9): 1599-1613. doi: 10.1161/CIRCRESAHA.116.303503
2. Rocha-Singh K. DiRectional AthErectomy + Drug CoAted BaLloon to Treat Long, Calcified Femoropopliteal ArterY Lesions VIVA REALITY: Primary Endpoint Assessments. *Vascular InterVentional Advances (VIVA)* 2020. Accessed March 11, 2021. Available online at <https://vivaphysicians.org/ondemand>
3. Zeller T, Brodmann M, Micari A, et al. Drug-coated balloon treatment of femoropopliteal lesions for patients with intermittent claudication and ischemic rest pain: one-year results of the IN.PACT Global Real-World Study. *Circ Cardiovasc Interv*. 2019 Jan 11; 12(1):e007730. doi: 10.1161/CIRCINTERVENTIONS.118.007730
4. McKinsey JF, Zeller T, Rocha-Singh KJ, Jaff MR, Garcia LA; DEFINITIVE LE Investigators. Lower extremity revascularization using directional atherectomy: 12-month prospective results of the DEFINITIVE LE study. *JACC Cardiovasc Interv*. 2014 Aug; 7(8): 923-333. doi: 10.1016/j.jcin.2014.05.006

This article is supported by Medtronic.

size is available. My increased use of IVUS has also brought better clinical outcomes for my patients, since I am no longer relying solely on a 2-dimensional view on angiography but the complete 3-dimensional view with color flow and real-time dynamics that you get with IVUS. Now on to the challenges. One problem with critical limb ischemia patients, especially lately, is in the efficiency of care. Delays come in getting patients COVID tested and in addressing patients' fears of getting COVID by coming to the hospital. A significant number are more willing to stay at home and let things auto amputate versus coming to the hospital and undergoing revascularization. We have been moving forward with CLI revascularizations in the setting of COVID, because it truly is a limb salvage procedure, while still being an elective procedure in my patient population. Those are some of the issues that I have seen lately. I do think that the advances in technology and understanding of the pathology have outweighed some of the cons that have come up in the setting of the pandemic.

For your CLI patients, is a directional atherectomy plus drug-coated balloon pathway fairly typical for revascularization?

Yes. By the time patients are in the CLI pathway, they have ABIs of 0.5, 0.4, or less, and usually a chronic total occlusion (CTO). I have seen some multifocal stenoses in CLI, but typically we are dealing with a CTO and the involvement of multiple vascular beds. More times than not, I am doing CTO recanalization in CLI patients with pre dilation, HawkOne™ Directional Atherectomy, and IN.PACT™ Admiral™ Drug-Coated Balloon (Medtronic) angioplasty, usually in the fem-pop region. After I have recanalized that region, I usually need to revascularize the tibials as well, because it is a multifocal vascular bed that is involved rather than a single lesion.

Any final thoughts?

The most important thing for CLI patients right now, particularly in our current pandemic setting, is being efficient in our care. I can't stress that enough. We want to get a patient revascularized quickly so they can get back to a sense of autonomy and independence, with a good quality of life. We've had to be a little creative in the pandemic setting. Even with something as simple as using anesthesia, we've had to answer the question, "Are these elective patients or not?" They aren't emergent, but are in need of urgent revascularization; otherwise, you are going to be dealing with a significantly higher rate of limb loss in the future. The most important thing is being diligent in trying to get these people taken care of. As hard as it was before, it is even harder now, but it is still doable.

The most important thing for CLI patients right now, particularly in our current pandemic setting, is being efficient in our care. I can't stress that enough. We want to get a patient revascularized quickly so they can get back to a sense of autonomy and independence, with a good quality of life.

James F. Foster III, MD, RVPI, and Miles McKee, DO
Centerpoint Medical Center,
Kansas City, Missouri



For US Audiences Only**HawkOne™ Directional Atherectomy System**

The HawkOne™ peripheral directional atherectomy system is intended for use in atherectomy of the peripheral vasculature. The HawkOne catheter is indicated for use in conjunction with the SpiderFX embolic protection device in the treatment of severely calcified lesions. The HawkOne catheter is NOT intended for use in the coronary, carotid, iliac or renal vasculature.

TrailBlazer™ Support Catheter

TrailBlazer™ Support Catheter are percutaneous, single lumen catheters designed for use in the peripheral vascular system. TrailBlazer™ Support Catheters are intended to guide and support a guide wire during access of the vasculature, allow for wire exchanges and provide a conduit for the delivery of saline solutions or diagnostic contrast agents.

CHOCOLATE™ PTA Balloon Catheter

The Chocolate™ PTA Balloon Catheter is intended for balloon dilatation of lesions in the peripheral vasculature, including the iliac, femoral, ilio-femoral, popliteal, infra-popliteal, and renal arteries.

IN.PACT™ Admiral™ Drug Coated PTA Balloon Catheter**Indications for Use:**

The IN.PACT™ Admiral™ Paclitaxel-coated PTA Balloon Catheter is indicated for percutaneous transluminal angioplasty, after appropriate vessel preparation, of de novo, restenotic, or in-stent restenotic lesions with lengths up to 360 mm in superficial femoral or popliteal arteries with reference vessel diameters of 4-7 mm.

Contraindications

The IN.PACT Admiral DCB is contraindicated for use in:

- Coronary arteries, renal arteries, and supra-aortic/cerebrovascular arteries
- Patients who cannot receive recommended antiplatelet and/or anticoagulant therapy
- Patients judged to have a lesion that prevents complete inflation of an angioplasty balloon or proper placement of the delivery system
- Patients with known allergies or sensitivities to paclitaxel
- Women who are breastfeeding, pregnant or are intending to become pregnant or men intending to father children. It is unknown whether paclitaxel will be excreted in human milk and whether there is a potential for adverse reaction in nursing infants from paclitaxel exposure.

Warnings

- A signal for increased risk of late mortality has been identified following the use of paclitaxel-coated balloons and paclitaxel-eluting stents for femoropopliteal arterial disease beginning approximately 2-3 years post-treatment compared with the use of non-drug coated devices. There is uncertainty regarding the magnitude and mechanism for the increased late mortality risk, including the impact of repeat paclitaxel-coated device exposure. Physicians should discuss this late mortality signal and the benefits and risks of available treatment options with their patients.
- Use the product prior to the Use-by Date specified on the package.
- Contents are supplied sterile. Do not use the product if the inner packaging is damaged or opened.
- Do not use air or any gaseous medium to inflate the balloon. Use only the recommended inflation medium (equal parts contrast medium and saline solution).
- Do not move the guidewire during inflation of the IN.PACT Admiral DCB.
- Do not exceed the rated burst pressure (RBP). The RBP is 14 atm (1419 kPa) for all balloons except the 200 and 250 mm balloons. For the 200 and 250 mm balloons the RBP is 11 atm (1115 kPa). The RBP is based on the results of in vitro testing. Use of pressures higher than RBP may result in a ruptured balloon with possible intimal damage and dissection.
- The safety and effectiveness of using multiple IN.PACT Admiral DCBs with a total drug dosage exceeding 34,854 µg of paclitaxel in a patient has not been clinically evaluated.

Precautions

- This product should only be used by physicians trained in percutaneous transluminal angioplasty (PTA).
- This product is designed for single patient use only. Do not reuse, reprocess, or resterilize this product. Reuse, reprocessing, or resterilization may compromise the structural integrity of the device and/or create a risk of contamination of the device, which could result in patient injury, illness, or death.
- Assess risks and benefits before treating patients with a history of severe reaction to contrast agents.
- The safety and effectiveness of the IN.PACT Admiral DCB used in conjunction with other drug-eluting stents or drug-coated balloons in the same procedure or following treatment failure has not been evaluated.
- The extent of the patient's exposure to the drug coating is directly related to the number of balloons used. Refer to the Instructions for Use (IFU) for details regarding the use of multiple balloons and paclitaxel content.

- The use of this product carries the risks associated with percutaneous transluminal angioplasty, including thrombosis, vascular complications, and/or bleeding events
- Vessel preparation using only pre-dilatation was studied in the clinical study. Other methods of vessel preparation, such as atherectomy, have not been studied clinically with IN.PACT Admiral DCB.
- This product is not intended for the expansion or delivery of a stent.

Potential Adverse Effects

The potential adverse effects (e.g. complications) associated with the use of the device are: abrupt vessel closure; access site pain; allergic reaction to contrast medium, antiplatelet therapy, or catheter system components (materials, drugs, and excipients); amputation/loss of limb; arrhythmias; arterial aneurysm; arterial thrombosis; arteriovenous (AV) fistula; death; dissection; embolization; fever; hematoma; hemorrhage; hypotension/hypertension; inflammation; ischemia or infarction of tissue/organ; local infection at access site; local or distal embolic events; perforation or rupture of the artery; pseudoaneurysm; renal insufficiency or failure; restenosis of the dilated artery; sepsis or systemic infection; shock; stroke; systemic embolization; vessel spasms or recoil; vessel trauma which requires surgical repair.

Potential complications of peripheral balloon catheterization include, but are not limited to the following: balloon rupture; detachment of a component of the balloon and/or catheter system; failure of the balloon to perform as intended; failure to cross the lesion.

Although systemic effects are not anticipated, potential adverse events that may be unique to the paclitaxel drug coating include, but are not limited to: allergic/immunologic reaction; alopecia; anemia; gastrointestinal symptoms; hematologic dyscrasia (including leucopenia, neutropenia, thrombocytopenia); hepatic enzyme changes; histologic changes in vessel wall, including inflammation, cellular damage, or necrosis; myalgia/arthralgia; myelosuppression; peripheral neuropathy.

Refer to the Physician's Desk Reference for more information on the potential adverse effects observed with paclitaxel. There may be other potential adverse effects that are unforeseen at this time.

Please reference appropriate product Instructions for Use for a detailed list of indications, warnings, precautions and potential adverse effects. This content is available electronically at www.manuals.medtronic.com. UC202118532EN © 2021 Medtronic. All brands are trademarks of their respective owners.